



Efficacy of a *Ceratothoa oestroides* Olive Oil Extract in Patients With Chronic Ulcers: A Pilot Study

The International Journal of Lower Extremity Wounds
1–8
© The Author(s) 2019
Article reuse guidelines:
sagepub.com/journals-permissions
DOI: 10.1177/1534734619856143
journals.sagepub.com/home/ijl



Andreas Vitsos, MSc¹, Christos Tsagarousianos, MD², Orestis Vergos, MD², Dionysios Stithos, MD², Dimitrios Mathioudakis, MD, MSc¹, Ioannis Vitsos, MD, PhD², Panayota Zouni, MD², Athina Kakolyri, MD², Evangelia Meimeti, PhD¹ , Maria Kyriazi, PhD¹, Ivi Antoniadou, PhD^{1,3}, Nikolaos Tentolouris, MD, PhD^{1,4}, Paraskevas Dallas, PhD¹, Vassilios Roussis, PhD¹, and Michail Rallis, PhD¹ 

Abstract

Chronic wounds unresponsive to existing treatments constitute a serious disease burden. Factors that contribute to the pathogenesis of chronic ulcers include oxidative stress, comorbid microbial infections, and the type of immune system response. Preclinically, and in a case study, a formulation containing a *Ceratothoa oestroides* olive oil extract promoted wound healing. Patients with chronic venous and pressure ulcers, clinically assessed as being unresponsive to healing agents, were treated for 3 months with an ointment containing the *C oestroides* extract combined with antibiotic and/or antiseptic agents chosen according to the type of bacterial infection. Treatment evaluation was performed using the Bates-Jensen criteria with +WoundDesk and MOWA cell phone applications. After 3 months of treatment, *C oestroides* resulted in an average decrease of 36% in the Bates-Jensen score of ulcers ($P < .000$), with the decrease being significant from the first month ($P < .007$). The combined use of topically applied antibiotics and antiseptics efficiently controlled microbial ulcer infection and facilitated wound healing. In relation to other factors such as initial wound size, chronicity appeared to be an important prognostic factor regarding the extent of wound healing. Future clinical investigations assessing the wound healing efficacy of the *C oestroides* olive oil extract are warranted.

Keywords

Ceratothoa oestroides, chronic wounds, healing, mixed A-V ulcers, stasis ulcers

Skin wounds heal through an orderly and timely repair process that results in anatomical and functional integrity.¹⁻³ The physiological wound healing process is dynamic, and if interrupted, an ulcer may become chronic.⁴ An estimated 2% of the population in Western countries will suffer from a chronic wound during their lifetime.^{5,6} Venous, arterial, diabetic, pressure, and traumatic ulcers may become non-healing lesions.⁷⁻¹⁰ Moreover, aging and comorbidities such as diabetes, venous insufficiency, obesity, and the presence of a microbial biofilm may contribute to healing failure.^{8,9,11-14} Parameters such as oxidative stress, the state of the innate immune system, and cutaneous neuromediators also significantly influence the wound healing process.¹⁵⁻¹⁷

Treatments for chronic, difficult-to-heal ulcers include debridement of the necrotic tissue, provision of a moist environment, pressure relief in the wound area, infection control, ischemia reversal, and comorbidity management.¹⁸⁻²² Various other therapies have been implemented,

such as vacuum-assisted closure, warming, oxygenation, transplantation of cells or skin grafts, administration of protein-rich plasma, and several types of impregnated dressings and natural products.^{23,24} Nonetheless, many chronic ulcers fail to heal and persist for months or even years.²⁵ Moreover, the ulcer may recur after healing, requiring additional wound care therapies.²² Currently, there is no fully satisfactory treatment, and new, efficient healing agents must be developed and introduced in clinical practice.¹

¹National and Kapodistrian University of Athens, Athens, Greece

²Zakynthos General Hospital Agios Dionysios, Zakynthos, Greece

³European University Cyprus, Nicosia, Cyprus

⁴Laiko General Hospital, Athens, Greece

Corresponding Author:

Michail Rallis, National and Kapodistrian University of Athens, Faculty of Pharmacy, Panepistimiopolis Zografou, Athens 15784, Greece.
Email: rallis@pharm.uoa.gr

During the past decade, a novel healing agent was investigated in our laboratory: an extract of the isopod *Ceratothoa oestroides* (Isopoda: *Cymothoidea*). In preclinical trials in mice, an olive oil extract of *C oestroides* exhibited substantial wound healing efficacy for both wounds and burns, without inducing toxicity.²⁶ Clinically, when the extract was combined with sodium eosin, it showed a remarkable capacity to heal very difficult-to-treat diabetic foot ulcers.²⁷

Ceratothoa oestroides is a ubiquitous protandric hermaphrodite fish parasite that settles in the buccal of wild fish species and is incapable of active migration to another host. The parasite initiates hematophagic nourishment, which comprises alternating cyclic periods of bloodsucking and blood absorption by its intestine.²⁸

The present study investigated whether the administration of a *C oestroides* olive oil extract in combination with antiseptics and/or antibiotics promotes the healing process of chronic venous and pressure ulcers in patients who previously received the standard-of-care treatment, which failed to induce wound healing.

Materials and Methods

Study Design

Outpatients were recruited from January to June 2017. All patients were inhabitants of Zakynthos Island in Southwestern Greece and were thus also monitored by the local primary hospital, Zakynthos General Hospital “Agios Dionysios.” Protocols were performed in compliance with the International Conference on Harmonization guidelines for Good Clinical Practice and the principles of the Declaration of Helsinki. All participants were thoroughly informed about the purposes of the study and provided written consent.

Eligible participants were adult patients who were diagnosed with one or more chronic skin ulcers that did not improve with prior conventional treatment. Exclusion criteria included a known allergy to seafood and/or the antibiotics or antiseptics used in the study, serious life-threatening complications, poorly controlled diabetes (glycated hemoglobin A1c [HbA1c]) >8.5% (>68 mmol/mol), pregnancy, breastfeeding, or an inability to read or write in Greek.

Patients

Fourteen volunteers aged 40 to 97 years (mean = 72 years and median = 75 years) were enrolled in the study. All patients were of Caucasian origin; 11 were female and 3 male. The patients suffered from one or more chronic, non-healing wounds (mean = 1.357 and median = 1) that either failed completely to close or exhibited a $\leq 20\%$ reduction in the ulcer area after proper standard-of-care treatment, including cleansing, debridement, infection control, and off-loading of the ulcer area, over 12 weeks.²⁹ The total

number of wounds examined was $n = 19$. Chronic ulcers were identified as pressure ($n = 12$), venous ($n = 6$), and a mixture of venous and arterial ($n = 1$) ulcers. All patients were incompetent, and the initial mean Bates-Jensen Wound Assessment Tool (BWAT) score of the wounds was 39.05 ± 4.23 (median = 39); accordingly, these wounds were considered very challenging from a therapeutic perspective.

Interventions

The extract was prepared after the addition of homogenized *C oestroides* to olive oil at a concentration of 10% w/w with stirring for 24 hours. The extract was then formulated as a fatty ointment. Wounds were cleansed with Ringers lactate or normal saline. Wounds infected with *Pseudomonas aeruginosa* were cleansed with 2% w/w acetic acid in normal saline.

Microbiological analysis of the wounds and related antimicrobial susceptibility tests were performed. Based on the findings from these assays, the antibiotics of choice were 0.5% gentamicin (Fagron Hellas SA, Trikala, Greece), 0.3% tobramycin (Fagron Hellas SA), and 10 000 IU/g polymyxin B (Fagron Hellas SA) or 500 IU/g bacitracin (Fagron Hellas SA). A treatment for gram-positive bacteria, 2% w/w sodium eosin (Fagron Hellas SA), was incorporated into the ointment as needed.

Wound care treatment was performed once daily. After cleansing the wound, a thin layer of the ointment was applied, covering the entire wound area. The wounds were then bandaged with suitable sterile dressings.

Assessments

Patients were visited at home at least once every 2 weeks (0.5 month) for 12 weeks (3 months). Images of the wounds were captured and assessed using the BWAT score,³⁰ either by conventional methods or the innovative cell phone applications +WoundDesk (digitalMedLab, Zürich, Switzerland)³¹ and MOWA,³² thus minimizing the subjectivity of the results.

Briefly, photographs were obtained at every meeting. Wound dimensions were measured automatically by the mobile applications (+WoundDesk and MOWA). In particular, a single-use paper reference area marker was placed beside the wound to enable automatic calculation of the wound surface (Figure 1). The following parameters were also scored: depth, edges, undermining, necrotic tissue type and amount, exudate type and amount, skin color surrounding the wound, peripheral tissue edema and induration, granulation tissue amount, and epithelialization. These data were stored in the +WoundDesk application (Figure 1).

Microbiological Tests

Microbiological tests were conducted every 15 days. Wound sampling was performed by rotating a sterile swab across the entire wound area. Cultures were performed on media

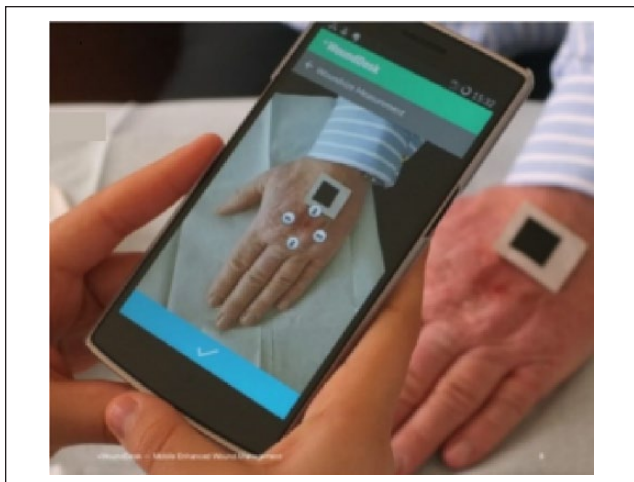


Figure 1. Wound evaluation by the +WoundDesk application.

suitable for microorganisms reported to contaminate and cause infections in chronic wounds (Blood Agar, MacConkey No. 2 Agar, and Sabouraud Dextrose Agar, Bioprep, Athens, Greece). Microbes were identified by microscopic observations (Gram staining) combined with biochemical testing (Kits and Reagents: Liofilchem Srl, Italy). Antimicrobial susceptibility tests were performed according to Clinical and Laboratory Standards Institute performance standards for antimicrobial susceptibility testing.

Data Analysis

Patients were divided into 2 groups: those suffering from pressure ulcers and those suffering venous ulcers. Data are presented as means \pm standard error of mean. The normality of BWAT scores was examined using Kolmogorov-Smirnov and Shapiro-Wilk tests with SPSS software (IBM SPSS software version 24.0 for Windows, Armonk, NY). As all data exhibited a normal distribution, repeated-measures analysis of variance followed by the least significant difference post hoc test were performed in order to examine statistically significant differences between the mean BWAT scores recorded at different time points. *T* tests were employed to assess statistically significant differences between mean BWAT scores at 2 time points. Pearson's correlation testing was conducted to evaluate correlations between wound healing and wound age or the wound surface.

Results

Microbiological Evaluation

The majority of wounds had a polymicrobial profile (Table 1). Necrotic tissue related to microbes, which was considered a microbial biofilm, was evident in most wounds on initiation of treatment (Figure 2). The most common infections

were caused by *P aeruginosa*, *Staphylococcus* spp, and *Staphylococcus aureus* (Table 1). Six wounds were infected with both *P aeruginosa* and *S aureus* (a mean 31.57% of the total wounds). Additionally, multi-drug-resistant microbes were identified in 3 cases: extended-spectrum β -lactamase-positive *Escherichia coli*, methicillin-resistant *S aureus*, and multidrug-resistant (MDR) *P aeruginosa*. Notably, the strain of MDR *P aeruginosa* was resistant to all antibiotics tested, with the exception of colistimethate sodium, which was used in combination with a 2% w/w acetic acid cleansing solution and eradicated the infection after 20 days of treatment.

Clinical Evaluation

The main characteristics of the patients and wounds are summarized in Table 2. The patients enrolled in the present study included 3 males and 9 females with 1 ulcer each, 1 female with 2 ulcers, and another female with 5 ulcers. The wound durations ranged from 3 months to 21 years (mean = 32.71 months and median = 8.5 months). All the wounds were assessed prior to the initiation of treatment. The average BWAT score was 39.05, and the median score was 39 (Table 3). As shown in Table 3, BWAT scores decreased after 3 months of treatment in all cases, ranging from 14.7% to 67.5% (mean = 36% and median = 38%).

Complete healing was achieved in 5 patients (1 venous and 4 pressure ulcers) during the study. In all cases, complete healing was observed between the 10th and 12th weeks. For pressure and venous ulcers, primary healing end points were calculated to be 33.33% and 14.28%, respectively.

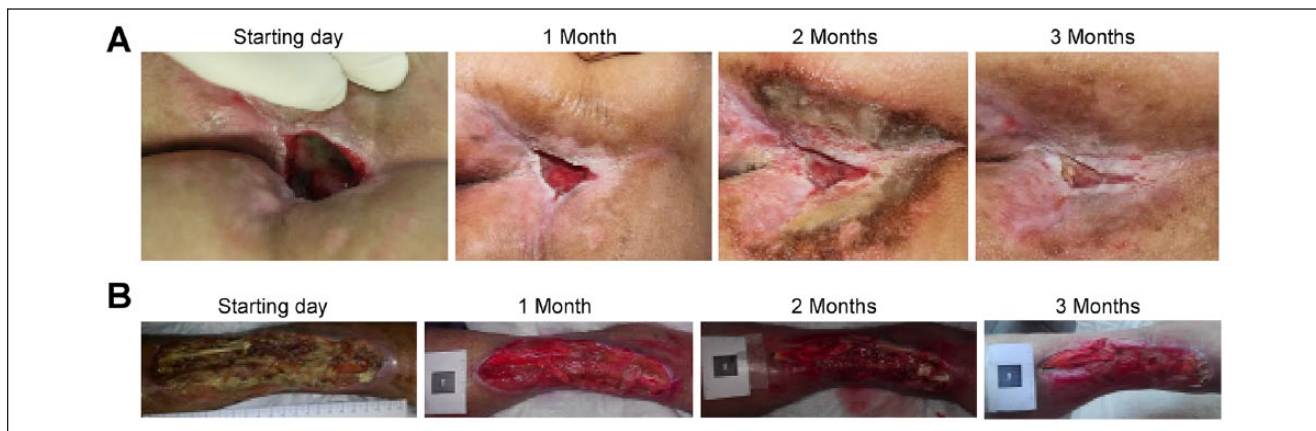
Representative images of the progressive healing of pressure and venous ulcers after 3 months of treatment with the *C oestroides* olive oil extract are presented in Figure 2. Both types of ulcers exhibited substantial improvement during the first month of treatment (Figure 3A). *C oestroides* exerted similar effects on both venous and pressure ulcers, and repeated-measures BWAT analysis of variance showed $P < .000$ in both cases. For both venous and pressure ulcers, the least significant difference post hoc test revealed a statistically significant decrease between the initial BWAT score and that of first month and all 0.5-month periods up to the third month (*P* values ranging from .007 to .000). However, no statistical significant decrease was obtained only for the first 0.5-month period ($P > .09$).

Based on the above observations, the reduction in the total BWAT scores for the venous and pressure ulcers following extract administration for 3 months were combined and plotted against the chronicity of the wound or the initial wound size. The degree of wound healing was negatively correlated with the chronicity of the wound (Figure 3B), whereas the initial size of the wound surprisingly did not influence wound healing (Figure 3C).

Table 1. Microbial Species That Colonized the Wounds Before Treatment.

Microbial Species	Number of Ulcers Colonized	% of Total Ulcers Colonized
<i>Pseudomonas aeruginosa</i> (of which 1 was MDR)	14	73.68
<i>Staphylococcus aureus</i> (of which 2 were MRSA)	13	68.42
<i>Staphylococcus</i> spp (coagulase negative)	10	52.63
<i>Proteus mirabilis</i>	8	42.10
<i>Escherichia coli</i> (of which 1 was ESBL)	6	31.58
<i>Candida albicans</i>	3	15.78
<i>Acinetobacter</i> spp	2	10.52
<i>Enterococcus faecalis</i>	1	5.26
<i>Serratia</i> spp	1	5.26

Abbreviations: MDR, multidrug-resistant; MRSA, methicillin-resistant *Staphylococcus aureus*; ESBL, extended-spectrum β -lactamase.

**Figure 2.** Three months after treatment. (A) Pressure and (B) venous wounds.**Table 2.** Patient Characteristics.

Patient ID	Age	Sex	Etiology	Wound History	Number of Wounds
1	97	Female	Pressure ulcer	5 months	1
2	94	Female	Pressure ulcer	3 months	1
3	62	Male	Pressure ulcer	7 months	1
4	82	Female	Pressure ulcer	21 years	1
5	40	Female	Pressure ulcer	2.5 years	1
6	78	Male	Pressure ulcer	10 months	1
7	58	Female	Pressure ulcer	3 years	5
8	80	Female	Venous ulcer	2 years	2
9	72	Female	Venous ulcer	5 months	1
10	50	Female	Venous ulcer	2.5 years	1
11	80	Female	Venous ulcer	3 months	1
12	70	Female	Mixture of venous and arterial ulcers	6 months	1
13	89	Female	Venous ulcer	5 months	1
14	67	Male	Pressure ulcer	3.5 years	1

Discussion

The *C oestroides* olive oil extract significantly regenerated chronic ulcers that were unresolved by other agents possessing antibacterial activity. Topical administration of

appropriate antibiotics and antimicrobial agents was effective against wound infections, inhibiting biofilm formation. Moreover, cleansing wounds with 2% w/w acetic acid solution helped significantly eradicate *P aeruginosa*. Wound

Table 3. Changes in the BWAT Score During 3-Month Treatment With the *Ceratothoa oestroides* Olive Oil Extract.

Ulcer ID	Initial BWAT Score	BWAT Score After 1 Month	BWAT Score After 2 Months	BWAT Score After 3 Months	% Reduction in the BWAT Score After 3 Months
Patient 1	41	29	22	18	56
Patient 2	40	20	17	13	67.5
Patient 3	39	26	25	23	41
Patient 4	33	26	23	22	33.33
Patient 5	45	29	22	19	57.77
Patient 6	38	36	28	23	39.47
Patient 7/ulcer 1	34	34	31	29	14.7
Patient 7/ulcer 2	39	36	34	24	38.46
Patient 7/ulcer 3	39	37	34	32	17.94
Patient 7/ulcer 4	46	43	40	38	17.39
Patient 7/ulcer 5	41	38	35	31	24.39
Patient 8/ulcer 1	46	41	43	38	17.39
Patient 8/ulcer 2	32	28	37	26	18.75
Patient 9	39	25	20	19	51.28
Patient 10	39	31	30	29	25.64
Patient 11	43	30	28	25	41.86
Patient 12	40	22	20	19	52.5
Patient 13	35	27	25	21	40
Patient 14	33	27	26	25	24.24

Abbreviation: BWAT, Bates-Jensen Wound Assessment Tool.

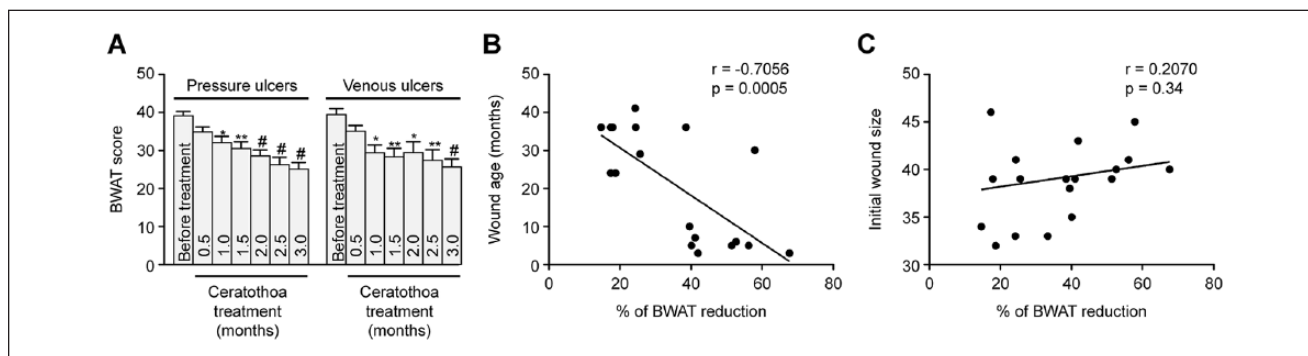


Figure 3. Bates-Jensen Wound Assessment Tool (BWAT) score: (A) Change in relation to treatment time. (B) Correlation with wound age. (C) Correlation with the initial wound size.

* $P < .05$, ** $P < .005$, # $P < .0001$.

chronicity should be considered as a major factor when treating such wounds, whereas the wound size or patient age may be only a secondary concern (Figure 3B and C).

In this study, all wounds were infected with bacteria, and the majority of the wounds were colonized by different types of microbes (Table 1). Many of those microbes were found to be resistant to antibiotics due to the formation of a biofilm with a polymicrobial profile. Gram-positive, pathogenic *S aureus* and nonpathogenic *Streptococcus* spp, as well as gram-negative *P aeruginosa* (Table 1), were the most commonly identified bacteria. All 3 bacteria have been reported to create biofilms at high rates, significantly

impairing wound healing.³³⁻³⁵ In addition, 32% of the patients presented a coinfection with *P aeruginosa* and *S aureus*, and coinfection with these 2 pathogens has been reported to exacerbate wound healing.³⁶ According to Lindsay et al,³⁷ *P aeruginosa*, *S aureus*, and *Streptococcus* spp produce proteases that destroy the host tissue, leading to the development of inflammatory responses and impaired wound healing. As shown in our study, chronic wounds are related to the existence of polymicrobial infections and biofilms, which is consistent with the literature.³⁸ In 20% of the cases in our study, the wounds were infected with MDR microbes. Remarkably, all patients infected with MDR

microbes had a chronic wound that lasted for 2 to 3 years or more and were repeatedly treated with antibiotics per os (by mouth) for long periods of time. This high incidence confirms that resistant microbes preferentially develop in chronic wounds.³⁹

A 2% w/w acetic acid solution was used as a cleansing agent and significantly contributed to *P aeruginosa* eradication, which has been confirmed by several studies.^{40,41} Based on microbiological susceptibility tests, the appropriate antibiotics were incorporated into the ointment and administered by topical application. In all cases, these antibiotics effectively controlled the infection during the first month of treatment. Therefore, microbial control via combinations of topically applied antibiotics and antiseptics was very efficient against all types of bacteria, even MDR bacteria. Accordingly, infection control is a predominant parameter contributing to effective wound healing. However, in preliminary studies performed in our laboratory in mice with noninfected wounds treated with different antibiotics and sodium eosin, we observed a significant delay in wound healing (unpublished data). Thus, infection control is a prevalent factor contributing to effective wound healing, but antimicrobial agents lack wound healing efficacy. The *C oestroides* olive oil extract also shows significant antibacterial activity against gram-negative bacteria (unpublished data), possibly contributing to the eradication of bacteria in infected wounds and facilitating wound healing.

Ceratothoa oestroides notably promoted skin regeneration, as it was an effective medication for chronic pressure or venous wounds. Considering the short study period and the severity of the wounds treated, the primary end point rate, especially for pressure ulcers, was remarkable. As shown in Table 3 and Figure 3A, the extract was most effective during the first month of treatment, and in the second and third months, the extract continued to promote wound healing but at a lower rate. This decrease in the wound healing rate has also been observed for chronic treatments with other commercial wound healing agents.⁴² Interestingly, patients with multiple wounds exhibited less of an improvement than did patients with a single wound. The reduction in BWAT scores was not correlated with the initial wound surface or the age of the patient, though wound chronicity was apparently negatively correlated with reduced BWAT scores (Figure 3B and C). Therefore, relatively recent wounds heal faster than do older ones.

The *C oestroides* olive oil extract significantly promoted wound healing but did not completely heal them in 3 months; it should be noted that the study was approved to be conducted for only 3 months. Therefore, studies investigating the healing of chronic, untreated wounds must be performed for a longer period of time. For example, when using allogeneic human keratinocyte cultures on chronic venous leg ulcers, complete wound closure was achieved

after 6 months at a rate of 41%, and this period was much longer than that of our study.⁴³ In another study testing low-level laser therapy for chronic venous leg ulcers, no effect was observed for the same time period of 3 months, leaving in question possible delayed effects.⁴⁴

In addition to the above-mentioned study time limitation, another main restriction was the decreased wound healing rate for such long-lasting chronic wounds, despite an initial relatively rapid healing period, achieving only 27.8% complete healing. Future studies are required to investigate the long-term efficacy of this extract. Another factor somewhat limiting the study was the lack of consideration of the nutrition status of the patients, a parameter that is strongly associated with wound healing.⁴⁵

The *C oestroides* extract has been consistently shown to promote skin regeneration in recent preclinical and clinical studies. The extract improved the healing of excision wounds, second-degree burns, and wounds induced by UV (ultraviolet) irradiation in preclinical studies, and healing in these cases was associated with a significant decrease in oxidative stress and inflammation of the wound area. The *C oestroides* extract has also been shown in clinical studies to heal diabetic and venous ulcers.^{27,42}

The mechanism of action of the *C oestroides* extract may be similar to that of other parasites such as helminths and fly larvae, but further studies are needed to elucidate the mechanism.^{46,47} In particular, some parasites activate Th2-mediated immunity, which appears to improve inflammation and wound healing.⁴⁸

New technologies such as cell phone applications may substantially improve patient monitoring and contribute to a more effective evaluation of chronic wounds. Overall, immediate and direct communication between care team members may be beneficial for patients.³²

In conclusion, the *C oestroides* olive oil extract showed substantial healing properties when applied to chronic, untreated wounds inducing significant decrease in wound size. Furthermore, the efficient microbial control by topically applied agents facilitated wound healing, inhibiting recurrence of wound infection. In relation to other factors such as the initial wound size, chronicity appeared to be an important prognostic factor for the extent of wound healing. Future clinical investigations assessing the wound healing efficacy of the *C oestroides* olive oil extract are warranted.

Authors' Note

Permission of the Scientific Committee of Laikon General Hospital, Athens, Greece (Protocol No. 1462/2016) and the Hellenic Data Protection Authority (License No. 1834, Athens, Greece).

Acknowledgments

We are grateful to digitalMedLab for generously providing the mobile phone application + WoundDesk.

Declaration of Conflicting Interests

The author(s) declared no potential conflicts of interest with respect to the research, authorship, and/or publication of this article.

Funding

The author(s) received no financial support for the research, authorship, and/or publication of this article.

ORCID iDs

Evangelia Meimeti  <https://orcid.org/0000-0002-5031-8629>

Michail Rallis  <https://orcid.org/0000-0002-3802-197X>

References

- Park JW, Hwang SR, Yoon IS. Advanced growth factor delivery systems in wound management and skin regeneration. *Molecules*. 2017;22:E1259. doi:10.3390/molecules22081259
- Childs DR, Murthy AS. Overview of wound healing and management. *Surg Clin North Am*. 2017;97:189-207. doi:10.1016/j.suc.2016.08.013
- Gonzalez AC, Costa TF, Andrade ZA, Medrado AR. Wound healing—a literature review. *An Bras Dermatol*. 2016;91:614-620. doi:10.1590/abd1806-4841.20164741
- Braund R, Hook S, Medlicott NJ. The role of topical growth factors in chronic wounds. *Curr Drug Deliv*. 2007;4:195-204. doi:10.2174/156720107781023857
- Gottrup F. A specialized wound-healing center concept: importance of a multidisciplinary department structure and surgical treatment facilities in the treatment of chronic wounds. *Am J Surg*. 2004;187:38S-43S. doi:10.1016/S0002-9610(03)00303-9
- Nelzen O, Bergqvist D, Lindhagen A, Hallböök T. Chronic leg ulcers: an underestimated problem in primary health care among elderly patients. *J Epidemiol Community Health*. 1991;45:184-187.
- Frykberg RG, Banks J. Challenges in the treatment of chronic wounds. *Adv Wound Care (New Rochelle)*. 2015;4:560-582. doi:10.1089/wound.2015.0635
- Okonkwo UA, DiPietro LA. Diabetes and wound angiogenesis. *Int J Mol Sci*. 2017;18:E1419. doi:10.3390/ijms18071419
- Vuorisalo S, Venermo M, Lepäntalo M. Treatment of diabetic foot ulcers. *J Cardiovasc Surg (Torino)*. 2009;50:275-291.
- Sorg H, Tilkorn DJ, Hager S, Hauser J, Mirastschijski U. Skin wound healing: an update on the current knowledge and concepts. *Eur Surg Res*. 2017;58:81-94. doi:10.1159/000454919
- Werdin F, Tennenhaus M, Schaller HE, Rennekampff HO. Evidence-based management strategies for treatment of chronic wounds. *Eplasty*. 2009;9:e19.
- de Souza KS, Cantaruti TA, Azevedo GM Jr, et al. Improved cutaneous wound healing after intraperitoneal injection of alpha-melanocyte-stimulating hormone. *Exp Dermatol*. 2015;24:198-203. doi:10.1111/exd.12609
- Wu CL, Kimmerling KA, Little D, Guilak F. Serum and synovial fluid lipidomic profiles predict obesity-associated osteoarthritis, synovitis, and wound repair. *Sci Rep*. 2017;7:44315. doi:10.1038/srep44315
- Strausberg J, Lehmann N, Kroger K, Maier I, Schneider H, Niebel W. Changes in secondary care may explain increasing pressure ulcer rates in a university clinic in Germany. *Wound Manage*. 2007;(5):194-198.
- Portou MJ, Baker D, Abraham D, Tsui J. The innate immune system, toll-like receptors and dermal wound healing: a review. *Vascul Pharmacol*. 2015;71:31-36. doi:10.1016/j.vph.2015.02.007
- Ashrafi M, Baguneid M, Bayat A. The role of neuromediators and innervation in cutaneous wound healing. *Acta Derm Venereol*. 2016;96:587-594. doi:10.2340/00015555-2321
- Goksen S, Balabanli B, Coşkun-Cevher Ş. Application of platelet derived growth factor-BB and diabetic wound healing: the relationship with oxidative events. *Free Radic Res*. 2017;51:498-505. doi:10.1080/10715762.2017.1327715
- Ahmed ME, Mohammed MS, Mahadi SI. Primary wound closure of diabetic foot ulcers by debridement and stitching. *J Wound Care*. 2016;25:650-654. doi:10.12968/jowc.2016.25.11.650
- Abela G. Benefits of maggot debridement therapy on leg ulcers: a literature review. *Br J Community Nurs*. 2017;22(suppl 6):S14-S19. doi:10.12968/bjcn.2017.22.Sup6.S14
- Kirker KR, James GA. In vitro studies evaluating the effects of biofilms on wound-healing cells: a review. *APMIS*. 2017;125:344-352. doi:10.1111/apm.12678
- Khor BYC, Price P. The comparative efficacy of angiosome-directed and indirect revascularization strategies to aid healing of chronic foot wounds in patients with comorbid diabetes mellitus and critical limb ischaemia: a literature review. *J Foot Ankle Res*. 2017;10:26. doi:10.1186/s13047-017-0206-5
- Martinez-Zapata MJ, Marti-Carvajal AJ, Solà I, et al. Autologous platelet-rich plasma for treating chronic wounds. *Cochrane Database Syst Rev*. 2012;(10):CD006899. doi:10.1002/14651858.CD006899.pub2
- Pereira RF, Bártolo PJ. Traditional therapies for skin wound healing. *Adv Wound Care (New Rochelle)*. 2016;5:208-229. doi:10.1089/wound.2013.0506
- Damir A. Recent advances in management of chronic non-healing diabetic foot ulcers. *J Inter Med Sci Acad*. 2011;24:219-223.
- Guihan M, Bombardier CH, Ehde DM, et al. Comparing multicomponent interventions to improve skin care behaviors and prevent recurrence in veterans hospitalized for severe pressure ulcers. *Arch Phys Med Rehabil*. 2014;95:1246-1253.e3. doi:10.1016/j.apmr.2014.01.012
- Rallis M, Koulourides I, Vitsos A, et al. Healing activity of different natural and chemical agents on experimental wounds. *Wound Repair Regen*. 2012;20:A107.
- Meimeti E, Psarou A, Loupa CV, et al. Treatment of diabetic foot ulcer with ointment based on *Ceratothoa oestroides* extract and eosin—case report. *Int J Med Pharm Case Rep*. 2017;9(5):1-6. doi:10.9734/IJMP/2017/35531
- Mladineo I. Life cycle of *Ceratothoa oestroides*, a cymothoid isopod parasite from sea bass *Dicentrarchus labrax* and sea bream *Sparus aurata*. *Dis Aquat Organ*. 2003;57:97-101. doi:10.3354/dao057097
- Sheehan P, Jones P, Giurini JM, Caselli A, Veves A. Percent change in wound area of diabetic foot ulcers over a

- 4-week period is a robust predictor of complete healing in a 12-week prospective trial. *Plast Reconstr Surg*. 2006;117(7 suppl):239S-244S.
30. Bates-Jensen BM. Chronic wound assessment. *Nurs Clin North Am*. 1999;34:799-845.
 31. Sigam PI, Denz M. Reliability and accuracy of wound surface measurement using mobile technology. *Int Soc Telemed eHealth*. 2015;8:365-369.
 32. Ciancio F, Portincasa A, Parisi D, Innocenti A. MowA®: a simple and economic way of monitoring chronic wounds outcome with your mobile devices. *Ann Ital Chir*. 2017;88:94.
 33. Rupp ME. Clinical characteristics of infections in humans due to *Staphylococcus epidermidis*. *Methods Mol Biol*. 2014;1106:1-16. doi:10.1007/978-1-62703-736-5_1
 34. Schierle CF, De la Garza M, Mustoe TA, Galiano RD. Staphylococcal biofilms impair wound healing by delaying reepithelialization in a murine cutaneous wound model. *Wound Repair Regen*. 2009;17:354-359. doi:10.1111/j.1524-475X.2009.00489.x
 35. Frei E, Hodgkiss-Harlow K, Rossi PJ, Edmiston CE Jr, Bandyk DF. Microbial pathogenesis of bacterial biofilms: a causative factor of vascular surgical site infection. *Vasc Endovascular Surg*. 2011;45:688-696. doi:10.1177/1538574411419528
 36. Hotterbeekx A, Kumar-Singh S, Goossens H, Malhotra-Kumar S. In vivo and in vitro interactions between *Pseudomonas aeruginosa* and *Staphylococcus* spp. *Front Cell Infect Microbiol*. 2017;7:106.
 37. Lindsay S, Oates A, Bourdillon K. The detrimental impact of extracellular bacterial proteases on wound healing. *Int Wound J*. 2017;14:1237-1247. doi:10.3389/fcimb.2017.00106
 38. Suleman L. Extracellular bacterial proteases in chronic wounds: a potential therapeutic target? *Adv Wound Care (New Rochelle)*. 2016;5:455-463. doi:10.1089/wound.2015.0673
 39. Mendo-Lopez R, Jasso L, Guevara X, et al. Multidrug-resistant microorganisms colonizing lower extremity wounds in patients in a tertiary care hospital, Lima, Peru. *Am J Trop Med Hyg*. 2017;97:1045-1048. doi:10.4269/ajtmh.17-0235
 40. Nagoba BS, Selkar SP, Wadher BJ, Gandhi RC. Acetic acid treatment of pseudomonal wound infections—a review. *J Infect Public Health*. 2013;6:410-415. doi:10.1016/j.jiph.2013.05.005
 41. Madhusudhan VL. Efficacy of 1% acetic acid in the treatment of chronic wounds infected with *Pseudomonas aeruginosa*: prospective randomised controlled clinical trial. *Int Wound J*. 2016;13:1129-1136. doi:10.1111/iwj.12428
 42. Grigoropoulos A, Zouridaki E, Sgontzou T, et al. P 144—Clinical evaluation of wound healing capacity of isopod *Ceratothoa oestroides* oil extract. *Free Radic Biol Med*. 2017;108(suppl 1):S67. doi:10.1016/j.freeradbiomed.2017.04.229
 43. Beele H, de la Brassine M, Lambert J, et al. A prospective multicenter study of the efficacy and tolerability of cryopreserved allogenic human keratinocytes to treat venous leg ulcers. *Int J Low Extrem Wounds*. 2005;4:225-233. doi:10.1177/1534734605282999
 44. Vitse J, Bekara F, Byun S, Herlin C, Teot L. A double-blind, placebo-controlled randomized evaluation of the effect of low-level laser therapy on venous leg ulcers. *Int J Low Extrem Wounds*. 2017;16:29-35. doi:10.1177/1534734617690948
 45. Haughey L, Barbul A. Nutrition and lower extremity ulcers: causality and/or treatment. *Int J Low Extrem Wounds*. 2017;16:238-243. doi:10.1177/1534734617737639
 46. Allen JE, Wynn TA. Evolution of Th2 immunity: a rapid repair response to tissue destructive pathogens. *PLoS Pathog*. 2011;7:e1002003. doi:10.1371/journal.ppat.1002003
 47. Horobin AJ, Shakesheff KM, Pritchard DI. Promotion of human dermal fibroblast migration, matrix remodelling and modification of fibroblast morphology within a novel 3D model by *Lucilia sericata* larval secretions. *J Invest Dermatol*. 2006;126:1410-1418. doi:10.1038/sj.jid.5700256
 48. Jovanovic K, Siebeck M, Gropp R. The route to pathologies in chronic inflammatory diseases characterized by T helper type 2 immune cells. *Clin Exp Immunol*. 2014;178:201-211. doi:10.1111/cei.12409